



ORAL MANIFESTATIONS IN CHILDREN UNDERGOING HEMODIALYSIS: A COMPREHENSIVE REVIEW OF CLINICAL FEATURES AND PATHOGENETIC MECHANISMS

Rakhmonova Shokhsanom Rakhim kizi

Independent Researcher of the Bukhara State Medical Institute,
Assistant of Fergana Medical Institute of Public Health

Abstract

Children with chronic kidney disease (CKD) undergoing hemodialysis are at high risk of developing oral complications due to systemic metabolic, immunological, and salivary alterations. Oral manifestations in this population are diverse and often underdiagnosed. To analyze the prevalence, clinical features, and pathogenetic mechanisms of oral manifestations in children undergoing hemodialysis. A comprehensive literature review was conducted focusing on studies related to oral health in pediatric CKD patients. Particular attention was given to dental hard tissue lesions, salivary changes, mucosal alterations, and periodontal conditions. Children undergoing hemodialysis commonly present with enamel hypoplasia, dental caries, xerostomia, gingival inflammation, and mucosal lesions. These manifestations are strongly associated with disturbances in mineral metabolism, salivary dysfunction, immune impairment, and uremic toxicity. Oral manifestations in children undergoing hemodialysis reflect systemic pathological processes and require an integrated diagnostic and therapeutic approach. Early identification and multidisciplinary management are essential to improve oral and overall health outcomes.

Keywords: Hemodialysis, chronic kidney disease, children, oral manifestations, enamel hypoplasia, xerostomia, periodontal disease, saliva.

Introduction

Chronic kidney disease (CKD) in children is a complex systemic condition that affects multiple organs and physiological systems. As the disease progresses to advanced stages, hemodialysis becomes necessary to sustain life. However, despite its life-saving role, hemodialysis does not fully correct the underlying metabolic and biochemical disturbances associated with renal dysfunction. These systemic



alterations have profound effects on the oral cavity, making children with CKD particularly vulnerable to various oral manifestations.

The oral cavity often reflects systemic health, and in children undergoing hemodialysis, it becomes a site where multiple патологик changes manifest simultaneously. Disturbances in calcium-phosphorus metabolism, vitamin D deficiency, metabolic acidosis, and secondary hyperparathyroidism significantly affect the development and integrity of dental hard tissues. At the same time, salivary gland dysfunction and immune alterations further compromise oral homeostasis [1.2.4].

Oral manifestations in children with CKD are diverse and include both hard and soft tissue lesions. Dental abnormalities such as enamel hypoplasia, delayed tooth eruption, and increased susceptibility to caries are frequently reported. In addition, salivary changes such as reduced flow rate and altered composition contribute to xerostomia and impaired protective functions of saliva. Periodontal and mucosal changes, including gingivitis, uremic stomatitis, and mucosal dryness, are also commonly observed [3.4].

Despite the clinical importance of these manifestations, they are often underestimated in routine medical care. Many studies focus on systemic complications of CKD, while oral health is considered a secondary issue. However, untreated oral diseases can negatively impact quality of life, nutritional status, and even systemic inflammation. Therefore, a comprehensive understanding of oral manifestations and their underlying pathogenetic mechanisms is essential for improving patient care. This review aims to summarize current knowledge on oral changes in children undergoing hemodialysis and to highlight the importance of an integrated, multidisciplinary approach.

Oral manifestations in children undergoing hemodialysis represent a complex interplay of systemic metabolic disturbances, salivary dysfunction, immune impairment, and local environmental factors. These changes affect both hard and soft tissues of the oral cavity and often progress rapidly due to the vulnerability of developing dental structures in children [5.6].

One of the most prominent features in this population is the high prevalence of dental hard tissue abnormalities. Disturbances in calcium-phosphorus metabolism, which are characteristic of chronic kidney disease (CKD), play a central role in the pathogenesis of these changes. Hypocalcemia, hyperphosphatemia, and vitamin D deficiency disrupt the mineralization process of enamel and dentin, leading to



structural defects. As a result, enamel hypoplasia, opacities, and reduced mineral density are frequently observed [7.8].

In children, these alterations are particularly significant because tooth development occurs simultaneously with systemic disease progression. Any disruption in mineral balance during odontogenesis may result in irreversible defects. These defects not only affect the эстетик aspect but also significantly reduce the resistance of teeth to cariogenic factors.

Table 1. Major oral manifestations in children undergoing hemodialysis

Category	Manifestation	Clinical significance
Dental hard tissues	Enamel hypoplasia	Structural weakness, caries risk
	Dental caries	Increased prevalence and progression
	Dentin hypersensitivity	Pain, reduced quality of life
Periodontal tissues	Gingivitis	Inflammation due to plaque accumulation
	Periodontitis	Tissue destruction in severe cases
Salivary changes	Xerostomia	Reduced cleansing and protection
	Low buffering capacity	Increased demineralization
Oral mucosa	Uremic stomatitis	Toxic effect of uremia
	Dry mucosa	Discomfort, infection risk

Salivary dysfunction is another key factor contributing to oral pathology in children undergoing hemodialysis. Saliva plays an essential role in maintaining oral homeostasis by providing lubrication, buffering acids, facilitating remineralization, and exerting antimicrobial effects. However, in CKD patients, salivary flow rate is often reduced due to fluid restriction, medication effects, and salivary gland dysfunction [8.9].

Reduced salivary secretion leads to xerostomia, which significantly impairs oral self-cleansing mechanisms. This promotes the accumulation of dental plaque and enhances the growth of cariogenic bacteria such as *Streptococcus mutans*. In addition, decreased buffering capacity limits the ability of saliva to neutralize acids, further accelerating enamel demineralization.

Interestingly, some studies report an increase in salivary pH in CKD patients due to elevated urea levels. However, this apparent alkalinity does not compensate for the reduced buffering capacity and impaired protective functions of saliva. Therefore, the overall effect remains detrimental to oral health.

Table 2. Pathogenetic mechanisms and their effects on oral health

Pathogenetic factor	Mechanism	Oral outcome
Mineral imbalance	Ca/P disturbance	Enamel hypoplasia, caries
Uremia	Toxic metabolites	Mucosal lesions, stomatitis
Salivary dysfunction	Reduced flow, altered pH	Xerostomia, plaque accumulation
Immune dysfunction	Reduced defense mechanisms	Gingivitis, infections
Metabolic acidosis	Mineral loss	Demineralization of enamel

Immune dysfunction further exacerbates oral pathology in children undergoing hemodialysis. CKD is associated with impaired immune response, including reduced neutrophil function and altered cytokine activity. This leads to increased susceptibility to infections and inflammatory conditions, particularly in the periodontal tissues.

Gingivitis is one of the most common findings, often progressing more rapidly than in healthy children. Poor oral hygiene, combined with reduced immune defense, creates favorable conditions for bacterial colonization and inflammation. In severe cases, periodontal destruction may occur, affecting both soft and hard supporting tissues [7.8].

Mucosal changes are also frequently observed. Uremic stomatitis, although less common, is a specific manifestation associated with elevated levels of urea and its breakdown products in saliva. Patients may also experience dryness, burning sensation, and discomfort, which negatively affect quality of life and oral function.

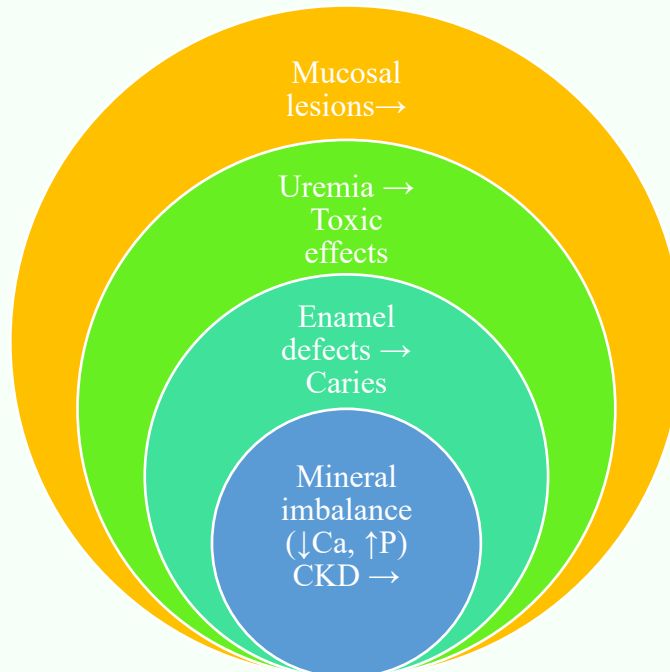


Figure 1. Pathogenetic pathways of oral manifestations in children undergoing hemodialysis

Overall, oral manifestations in children undergoing hemodialysis are multifactorial and reflect the systemic nature of CKD. The interaction between metabolic, salivary, and immunological factors creates a high-risk environment for the development and progression of oral diseases. Understanding these mechanisms is essential for improving prevention and treatment strategies.

DISCUSSION

The findings of this review highlight that oral manifestations in children undergoing hemodialysis are not isolated clinical conditions but represent a direct consequence of systemic pathological processes associated with chronic kidney disease (CKD). The oral cavity serves as a sensitive indicator of metabolic, immunological, and biochemical disturbances, and therefore reflects the severity and progression of the underlying disease.

One of the central aspects discussed in this review is the role of mineral metabolism disorders in the development of dental hard tissue abnormalities. Disturbances in calcium-phosphorus balance, vitamin D deficiency, and secondary hyperparathyroidism significantly impair enamel and dentin mineralization. These



alterations are particularly critical in children, as dental tissues are still developing. Consequently, structural defects such as enamel hypoplasia and reduced mineral density are commonly observed, predisposing teeth to increased susceptibility to caries and mechanical damage.

In addition to mineral imbalance, salivary dysfunction plays a pivotal role in the pathogenesis of oral diseases in this population. Reduced salivary flow rate and buffering capacity compromise the natural protective mechanisms of the oral cavity. Although elevated salivary pH has been reported in CKD patients due to increased urea levels, this does not provide sufficient protection against acid-mediated demineralization. Instead, the reduced ability to neutralize acids and cleanse the oral environment leads to plaque accumulation and microbial overgrowth.

The role of immune dysfunction further complicates the clinical picture. CKD-associated alterations in immune response increase susceptibility to infections and inflammatory conditions. This is reflected in the high prevalence of gingivitis and, in some cases, progression to more severe periodontal disease. The interaction between impaired immunity and increased bacterial load creates a cycle of chronic inflammation that accelerates oral tissue damage.

Mucosal manifestations, including uremic stomatitis and mucosal dryness, are additional indicators of systemic toxicity and metabolic imbalance. Although less frequently reported than dental and periodontal changes, these conditions significantly affect patient comfort and quality of life. Their presence underscores the importance of considering oral health as an integral part of systemic disease management.

Importantly, this review emphasizes the multifactorial nature of oral pathology in children undergoing hemodialysis. No single factor can fully explain the observed clinical changes. Instead, it is the combined effect of metabolic disturbances, salivary dysfunction, immune impairment, and local factors that drives disease progression. This understanding has important clinical implications.

From a therapeutic perspective, the findings support the need for a comprehensive and multidisciplinary approach to oral health management in this population. Conventional dental care, focused solely on mechanical plaque removal and treatment of existing lesions, is insufficient. Instead, strategies should include early diagnosis, monitoring of biochemical parameters, support of salivary function, and preventive measures tailored to the specific needs of CKD patients.



Furthermore, collaboration between nephrologists and dental professionals is essential to ensure integrated patient care. Early intervention during childhood may prevent irreversible damage to dental structures and improve long-term oral and systemic health outcomes.

CONCLUSION

Oral manifestations in children undergoing hemodialysis are closely associated with systemic disturbances characteristic of chronic kidney disease and should be considered a reflection of underlying metabolic and immunological alterations. Mineral metabolism disorders, particularly calcium-phosphorus imbalance, play a key role in the development of dental hard tissue defects such as enamel hypoplasia and increased caries susceptibility. Salivary dysfunction, including reduced flow rate and buffering capacity, significantly contributes to the disruption of oral homeostasis and promotes the progression of dental and periodontal diseases. Immune impairment and uremic toxicity further exacerbate oral pathology, leading to increased inflammation, infection risk, and mucosal alterations. Effective management of oral health in children undergoing hemodialysis requires a comprehensive, multidisciplinary approach that integrates systemic and local factors, emphasizes early prevention, and includes regular monitoring of salivary and biochemical parameters.

REFERENCES

1. Kshirsagar, A. V., Moss, K. L., Elter, J. R., Beck, J. D., & Offenbacher, S. (2005). Periodontal disease is associated with renal insufficiency in the Atherosclerosis Risk in Communities (ARIC) study. *American Journal of Kidney Diseases*, 45(4), 650–657.
2. Davidovich, E., Davidovits, M., Eidelman, E., Schwarz, Z., & Bimstein, E. (2005). Pathophysiology, therapy, and oral implications of renal failure in children and adolescents. *Pediatric Dentistry*, 27(2), 98–106.
3. Nunn, J. H., Sharp, J., Lambert, H. J., Plant, N. D., & Coulthard, M. G. (2000). Oral health in children with renal disease. *Pediatric Nephrology*, 14(10–11), 997–1001.
4. Klassen, J. T., & Krasko, B. M. (2002). The dental health status of dialysis patients. *Journal of the Canadian Dental Association*, 68(1), 34–38.



5. Bots, C. P., Brand, H. S., Veerman, E. C., van Amerongen, B. M., Valentijn-Benz, M., & Veerman, E. C. (2006). Oral and salivary changes in patients with end stage renal disease. *Clinical Oral Investigations*, 10(1), 17–21.
6. Kho, H. S., Lee, S. W., Chung, S. C., & Kim, Y. K. (1999). Oral manifestations and salivary flow rate, pH, and buffer capacity in patients with end-stage renal disease. *Oral Surgery, Oral Medicine, Oral Pathology, Oral Radiology, and Endodontology*, 88(3), 316–319.
7. Proctor, R., Kumar, N., Stein, A., Moles, D., & Porter, S. (2005). Oral and dental aspects of chronic renal failure. *Journal of Dental Research*, 84(3), 199–208.
8. Bayraktar, G., Kurtulus, I., Kazancioglu, R., Bayramgurler, D., Bural, C., & Bozfakioglu, S. (2007). Evaluation of periodontal parameters in patients undergoing peritoneal dialysis or hemodialysis. *Oral Diseases*, 13(4), 393–397.
9. Craig, R. G. (2008). Interactions between chronic renal disease and periodontal disease. *Oral Diseases*, 14(1), 1–7.
10. Fisher, M. A., Taylor, G. W., Shelton, B. J., Jamerson, K. A., Rahman, M., Ojo, A. O., & Sehgal, A. R. (2008). Periodontal disease and other nontraditional risk factors for CKD. *American Journal of Kidney Diseases*, 51(1), 45–52.